



Photo Guide




Preparation List



Digital Camera with Macro Lens

Settings: ISO 100 and shutter speed 1/200 sec.



Photographic or Palatal Mirrors



Cheek Retractors

General Reminders

1. Make sure that the patient's mouth is free of debris and distractions
2. For occlusal pictures, please submerge the mirror in warm water to prevent from fogging up
3. To avoid shadows, please use non-distracting background
4. Use the camera's auto flash instead of surgery lights
5. Please turn and flip mirror photos horizontally for correct display
6. Always keep the camera horizontal and stand in front of the patient to avoid angulation



Extra-oral photos

Amount	4
Background	White
Adjustment	Aperture f/8 and Autofocus (AF) On
Distance	1.5mm, marking spots on the floor is highly recommended
Repose Photo	Patient looks forward, lips relaxed, teeth together, chin parallel to the floor
Smile Photo	Teeth together with a natural smile

Intra-oral photos

Amount	5
Positioning	Patient can sit in a dental chair for easy positioning and use cheek retractors
Adjustment	Manual focus and Aperture f/22

Extra-oral Photos (Examples)



Frontal view

- Natural head position
- Head should not be tilted
- Face should not be rotated
- Tooth jaw and lips in relaxed position
- Inter-pupillary line should be leveled



Frontal view - smiling

- It is same as the frontal view
- The patient should be smiling
- Tooth visible in a natural way
- This view aids in visualizing the patient's smile



Profile view

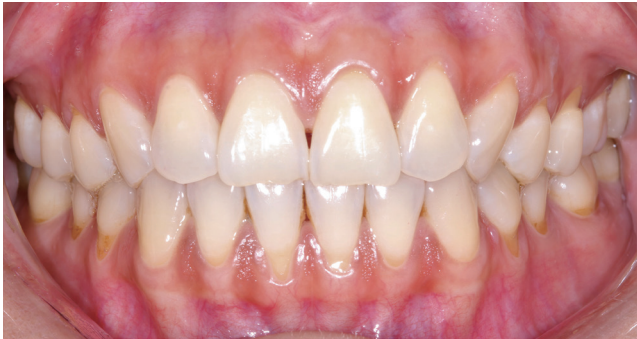- Turn to LEFT side
- Keeping head in natural position
- Eyes fixed horizontally at a specific point at eye level



Profile view - smiling

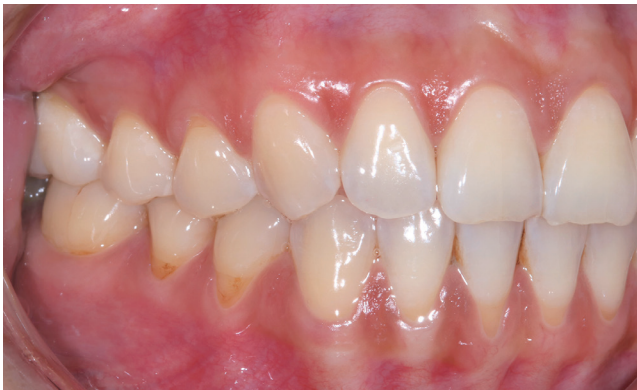- It is same as profile view
- When smiling, should see the anterior teeth
- The patient's whole side should be visible with no obstructions with hairs, hats or scarfs

Intra-oral Photos (Examples)



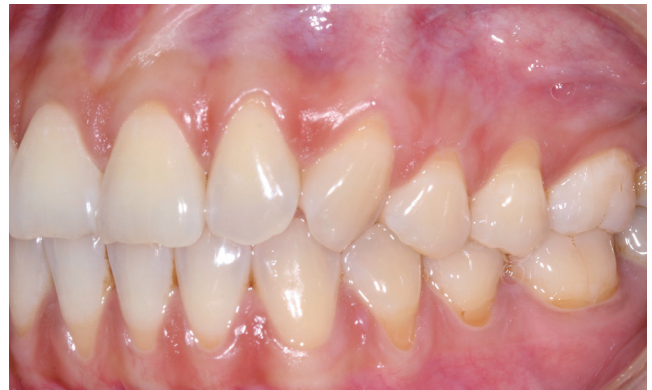Frontal view intra-oral

- Retraction on the cheeks and lips sideways and from tooth and gingiva
- The photo should be taken perpendicular to midline
- The centerline of the photo should match the occlusal plane



Right buccal view intra-oral

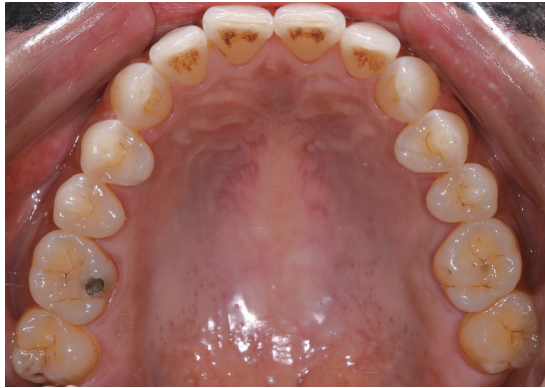- The patient's cheeks and lips must be retracted to the right side
- If possible, it is best to show the last molar
- At least the first molar should be shown in the photo
- The centerline of the photo should match the occlusal plane



Left buccal view intra-oral

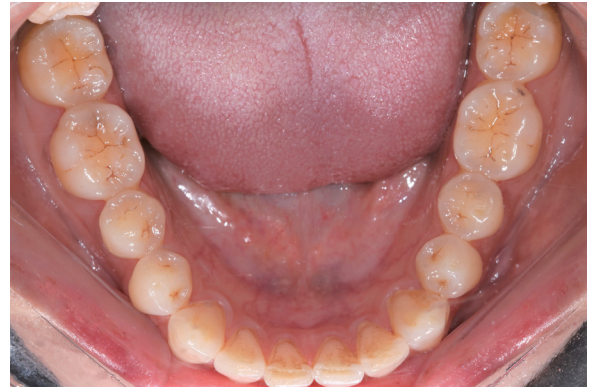- The patient's cheeks and lips must be retracted to the left side
- If possible, it is best to show the last molar
- At least the first molar should be shown in the photo
- The centerline of the photo should match the occlusal plane

Intra-oral Photos (Examples)



Maxillary Occlusal View

- Wider side of the mirror is inserted inward to capture the maximum with posteriorly
- The mid palatine raphe is taken as guide to center of photo
- It is taken perpendicular to plane of mirror



Mandibular Occlusal View

- Wider side of the mirror is inserted inward to capture the maximum with posteriorly
- The frenum of tongue is taken as guide to center of photo
- If possible, patient is asked to roll back the tongue behind the mirror for best view

Get started today!

Connect with our team at TrioClear@ModernDentalCanada.com
or call **800.361.6699** to start your treatment journey with us.